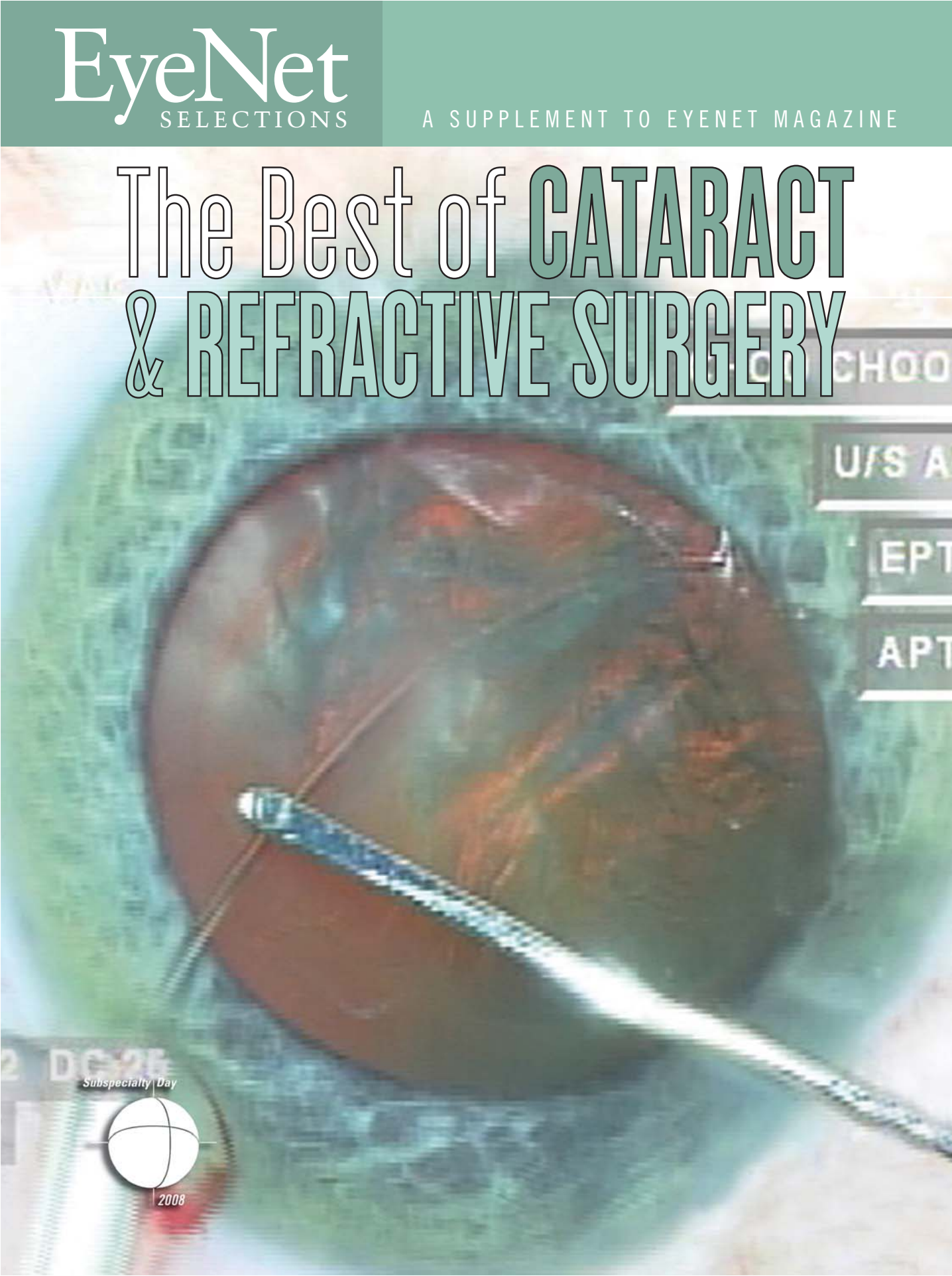

The Best of CATARACT & REFRACTIVE SURGERY



U/S A

EPT

APT

Subspecialty Day



2008

CATARACT

New Pupil Expansion Ring for Floppy Iris

BY BARBARA BOUGHTON, CONTRIBUTING WRITER

As the population ages, an increasing number of ophthalmology patients are likely to present with the condition known as intraoperative floppy iris syndrome (IFIS). Resulting from treatment with tamsulosin (Flomax) as well as other systemic alpha antagonists prescribed for benign prostatic hyperplasia, IFIS can result in poor pupil dilation, iris billowing and floppiness, iris prolapse to the incisions and progressive miosis.

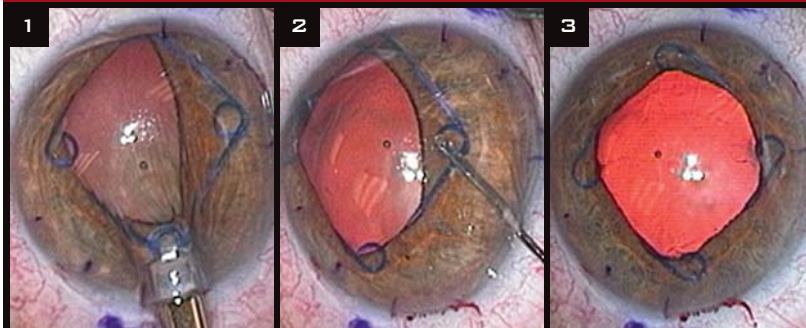
There are a number of techniques that the cataract surgeon can use to deal with IFIS, including preoperative atropine drops, intracameral injection of alpha agonists, the use of Healon 5 with low aspiration flow and vacuum, and, finally, mechanical devices that expand and maintain the pupil diameter during surgery. Such devices include iris retractors and a variety of different pupil expansion rings.

New Ring on the Block

The newest of the expansion rings is the Malyugin ring (MicroSurgical Technology, or MST). Developed by Boris Malyugin of Russia, the foldable square device is made of polypropylene and is much thinner than other rings, making it easier and safer to manipulate inside the eye, according to David F. Chang, MD, who, along with John R. Campbell, MD, first reported IFIS syndrome in cataract patients.¹ “The

This article originally appeared in the January 2008 issue of EyeNet Magazine.

Malyugin Ring Goes to Work



(1) After insertion into the anterior chamber with a disposable injector, the lead and lateral scrolls of the Malyugin ring engage the iris margin. (2) A Lester hook is used to position final scroll. (3) The ring creates 6-mm diameter pupil.

Malyugin ring has the thin profile of an IOL haptic, and so it doesn't get in the way of our instruments during surgery. It's easy to avoid corneal contact during insertion," said Dr. Chang, who is clinical professor of ophthalmology at the University of California, San Francisco. The loading and injection system, in contrast to those for other pupil expansion rings, is also disposable. The flexible device is injected into the anterior chamber, where its four circular coils engage the pupil edge to expand it, according to Dr. Chang.

Go easy on the iris. Because of how the iris drapes over it, the Malyugin ring, in contrast to iris retractors, creates a rounded rather than a square pupillary opening. It expands the pupil without overly stretching or traumatizing it, and is therefore very gentle on the iris, according to Dr. Chang. “The clever injector system devised by MST is used

to both insert and remove the ring from the anterior chamber,” Dr. Chang noted. “The learning curve is very fast, and it can be inserted more quickly than iris retractors, making this an ideal technique for resident cases,” he added.

Dr. Chang noted that he has done 30 IFIS and small-pupil cases with the Malyugin ring, and the outcomes have been excellent. As with other devices that mechanically expand the pupil, the Malyugin ring is particularly useful for severe IFIS. “Because the ring is so thin and light, it is still mobile enough to allow the iris to occasionally prolapse to the side port incision,” Dr. Chang added. “However, the pupil obviously cannot constrict,” he said. “If the ring seems to de-center to one side, one lateral scroll has probably hooked the edge of the capsulorhexis, and can simply be disengaged with a Lester hook.”

I. Howard Fine, MD, has also used

the Malyugin ring and calls it “very atraumatic. It goes in quite easily, and holds the pupil in an expanded way with a nice 6-mm pupillary opening. It’s very easy to work with; rather than being a full 1 mm, it’s like a thin paper clip,” said Dr. Fine, clinical professor of ophthalmology at Oregon Health & Science University in Portland.

Older Rings

Pupil expansion rings that have been in use for a while now include the Morcher 5S Pupil Ring and the Milvella Perfect Pupil—both of which are threaded along the pupillary margin using a metal injector. The Eagle Vision Graether ring is a disposable silicone pupil expansion ring that uses a plastic injector. However, all of these rings are difficult to position if the anterior chamber is shallow or the pupil is less than 4 mm wide.

Graether. The Graether is a soft silicone ring grooved to engage the iris sphincter and maintain pupil dilation. The pupil expander is preloaded onto a disposable insertion tool that allows the ring to be inserted through the primary surgical incision. An iris-glide retractor fixates the iris sphincter at the incision prior to insertion, according to John M. Graether, MD, who developed the ring and is in private practice in Marshalltown, Iowa.

Dr. Graether estimates that in his practice, he sees IFIS in 3 to 4 percent of his patients, and he uses the Graether ring on up to 10 to 15 percent of his patients because they may have either IFIS or another condition in which the pupil does not dilate well. In contrast, he finds iris retractors problematic. “They put pressure and indentations on the iris,” he said. Dr. Graether estimates that his ring can be inserted in about 30 seconds.

Milvella. Strategies for dealing with IFIS often depend on the preference of the surgeon, according to Robert M. Kershner, MD. He prefers using the Perfect Pupil expansion ring for severe cases of IFIS. It was developed in the 1990s by John E. Milverton, MD, of Australia, and is a sterile, disposable, polyurethane ring with an integrated arm that allows for insertion into the eye

and removal after surgery. It is inserted through an unenlarged clear corneal incision, according to Dr. Kershner, who is clinical professor of ophthalmology at the University of Utah in Salt Lake City. Capsulorhexis, hydrodissection, phacoemulsification and IOL insertion can all be safely carried out with the Perfect Pupil expansion ring in place.

“It’s easy to get in and out, and it can expand the pupil to 7 to 8 mm,” said Dr. Kershner. It also covers the pupillary sphincter on both sides. “This provides added protection because it’s possible during surgery to hit the pupil with the phaco tip.” Dr. Kershner has used it with a variety of IFIS cases. “Often the choice a surgeon will make in IFIS cases depends on their experience as well as their comfort level with different devices,” he said.

Morcher. Dr. Fine has used the Morcher pupil expansion ring as well as the Malyugin ring and notes that removal technique is important with the Morcher ring. When removing the Morcher, he noted, the leading edge of the ring should be perpendicular to the incision, and the ring can then be caught with the hook of the injection system. “If you use this technique, the ring can be removed comfortably and safely.”

IFIS Update

IFIS was first described in 2005 by Drs. Chang and Campbell in a retrospective/prospective study of 1,600 patients. Dr. Chang agreed that while IFIS was first reported with the use of tamsulosin, it is also seen with other alpha₁ blockers such as doxazosin (Cardura), terazosin (Hytrin) and alfuzosin (Uroxatral), a possibility that had been suggested early on by Dr. Kershner.² However, the frequency and severity of IFIS is apparently more severe with Flomax, perhaps because of its greater affinity for the alpha_{1a} receptor subtype, which is present in both the prostate and the iris dilator muscle, according to Dr. Chang.

Following the 2005 report by Drs. Chang and Campbell, the FDA approved a labeling change for Flomax, noting that “the patient’s ophthalmologist should be prepared for possible modifications to their surgical technique.” The

manufacturer of Flomax now includes a warning in its direct-to-consumer advertisements.

When using iris retractors, Dr. Chang recommends placing them in a diamond configuration.³ The subincisional hook retracts the iris downward and out of the path of the phaco tip—in contrast to a square iris hook configuration, which tents the iris up into the path.

In an audience poll on complicated cases at the 2007 Annual Meeting in New Orleans, iris retractors were the most popular method for dealing with IFIS during cataract surgery.

Plan ahead. When the surgeon knows the patient is taking tamsulosin, available strategies can provide positive outcomes. In a prospective multicenter study published in *Ophthalmology*, Dr. Chang and fellow researchers studied 167 consecutive eyes in 135 patients taking tamsulosin. Phacoemulsification was performed with at least one of four different IFIS strategies, including topical atropine, iris retractors, pupil expansion rings or Healon 5 with reduced fluidic parameters.⁴

The results showed that although 73 percent of patients had moderate or severe IFIS, the rate of posterior capsular rupture and vitreous loss was only 0.6 percent. The study revealed that 95 percent of the eyes also achieved a best-corrected visual acuity of at least 20/40.

“When experienced surgeons could anticipate IFIS and employ compensatory surgical techniques, the complication rate from cataract surgery was low and the visual outcomes were excellent in eyes of patients with a history of tamsulosin use,” Dr. Chang and fellow authors concluded.

Drs. Chang, Fine and Kershner report no related financial interests. Dr. Graether has a patent interest in the Eagle Vision ring.

1 Chang D. F. and J. R. Campbell. *J Cataract Refract Surg* 2005;31:664–673.

2 Kershner, R. M. *J Cataract Refract Surg* 2005;31:2239–2240.

3 Oetting, T. A. and L. C. Omphroy. *J Cataract Refract Surg* 2002;28:596–598.

4 Chang, D. F. et al. *Ophthalmology* 2007; 114(5):957–964.